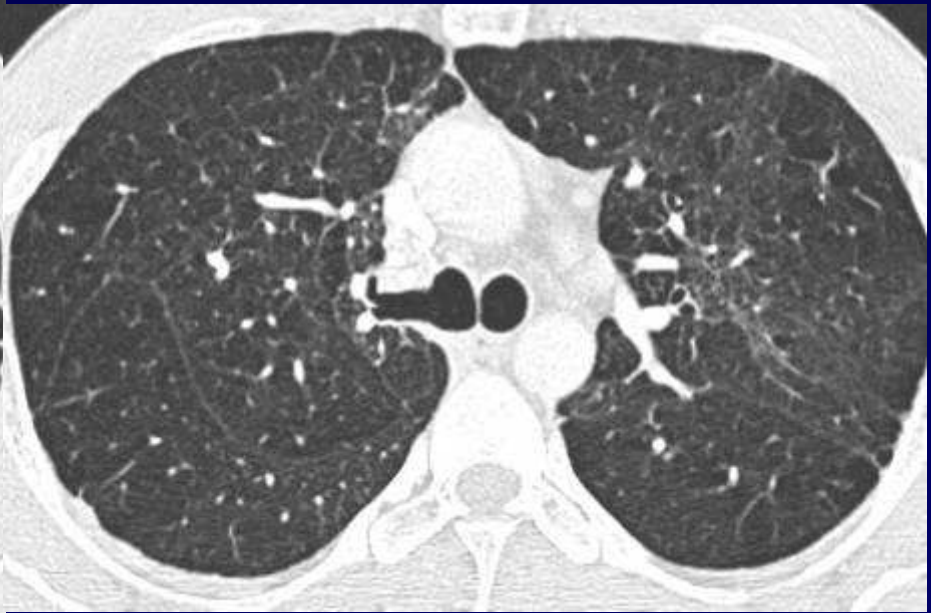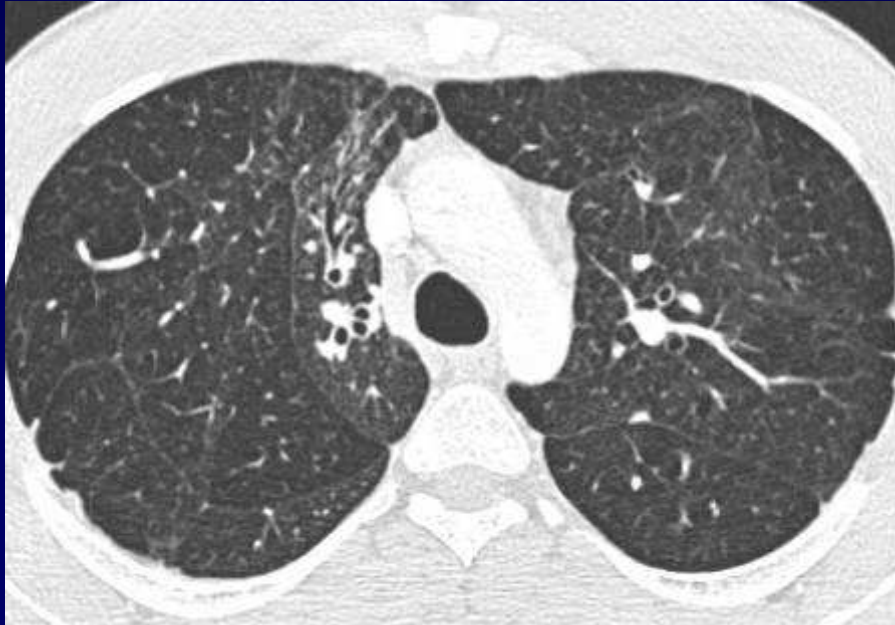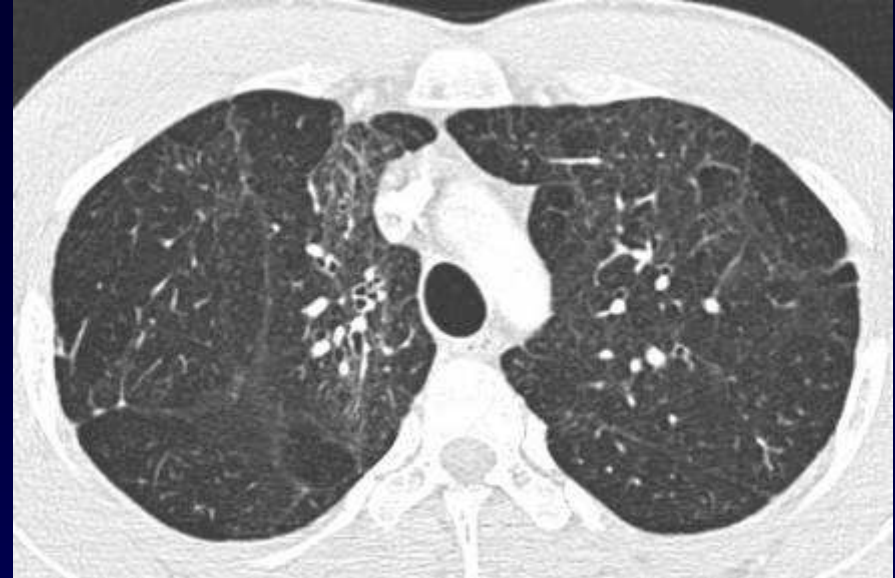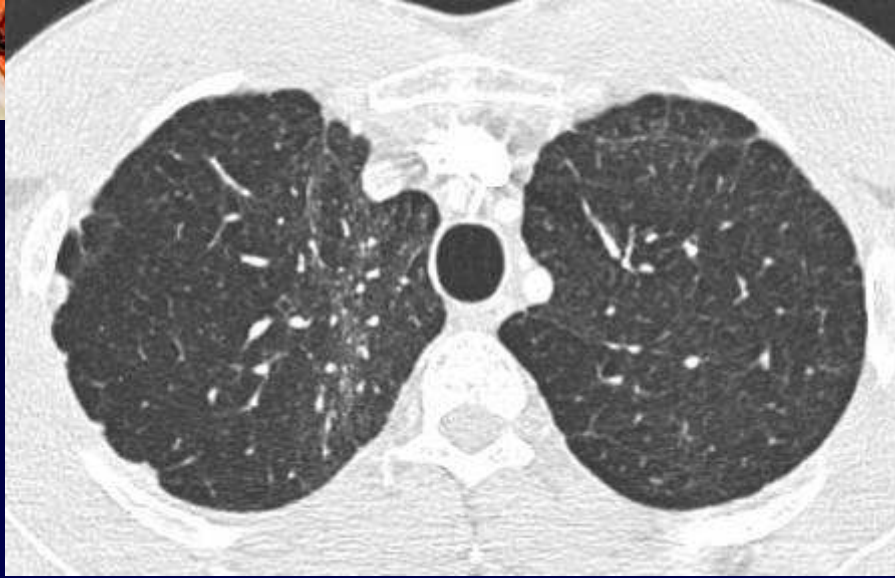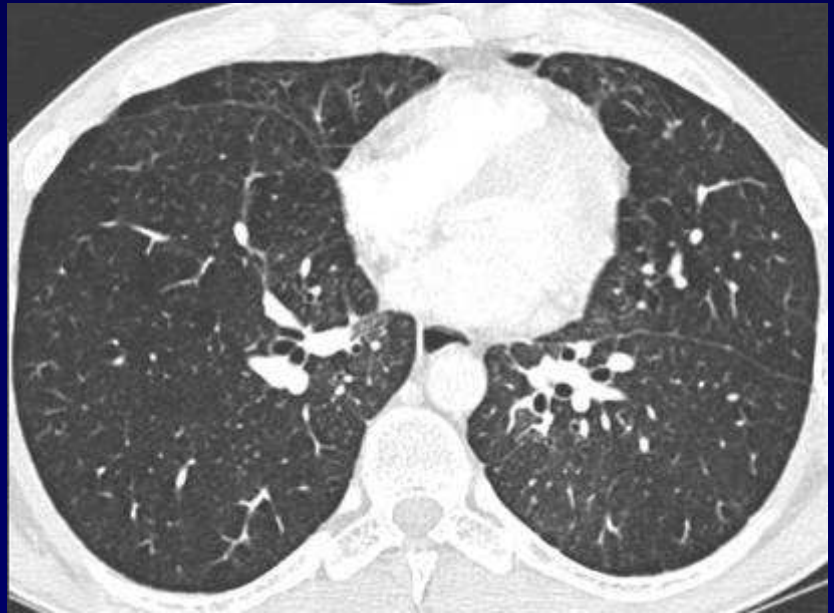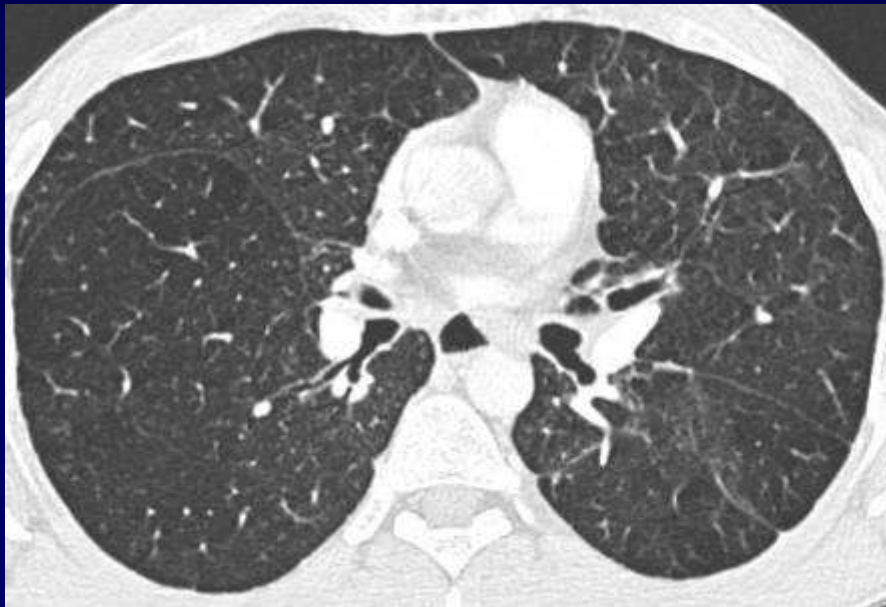


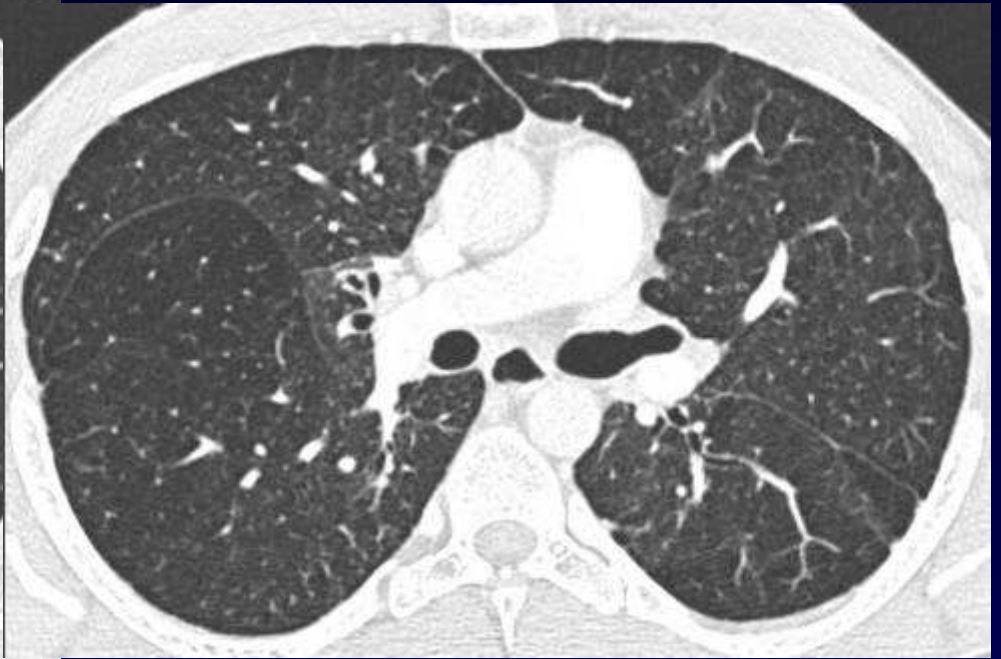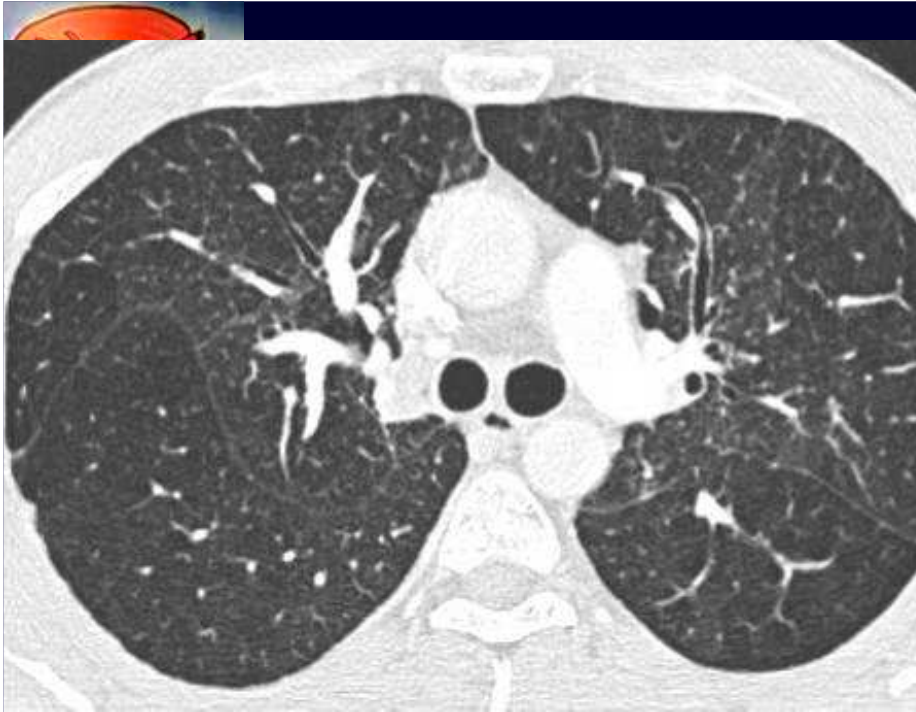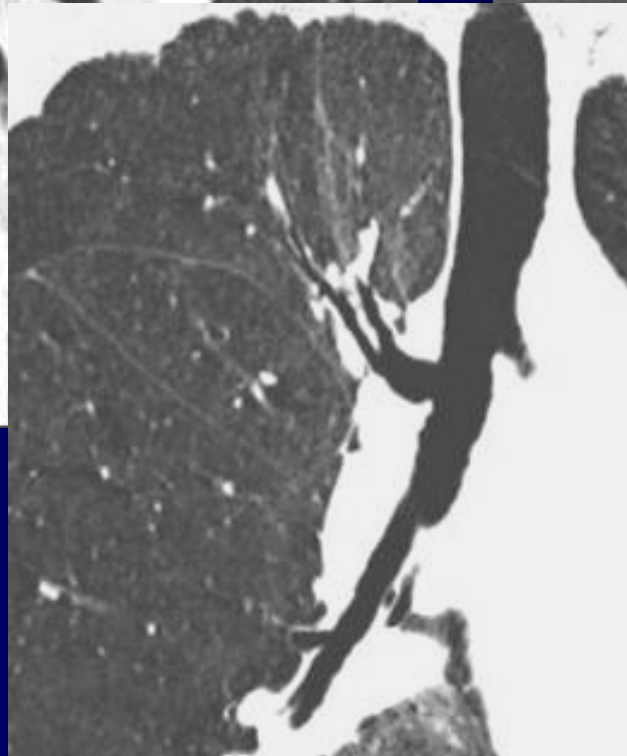
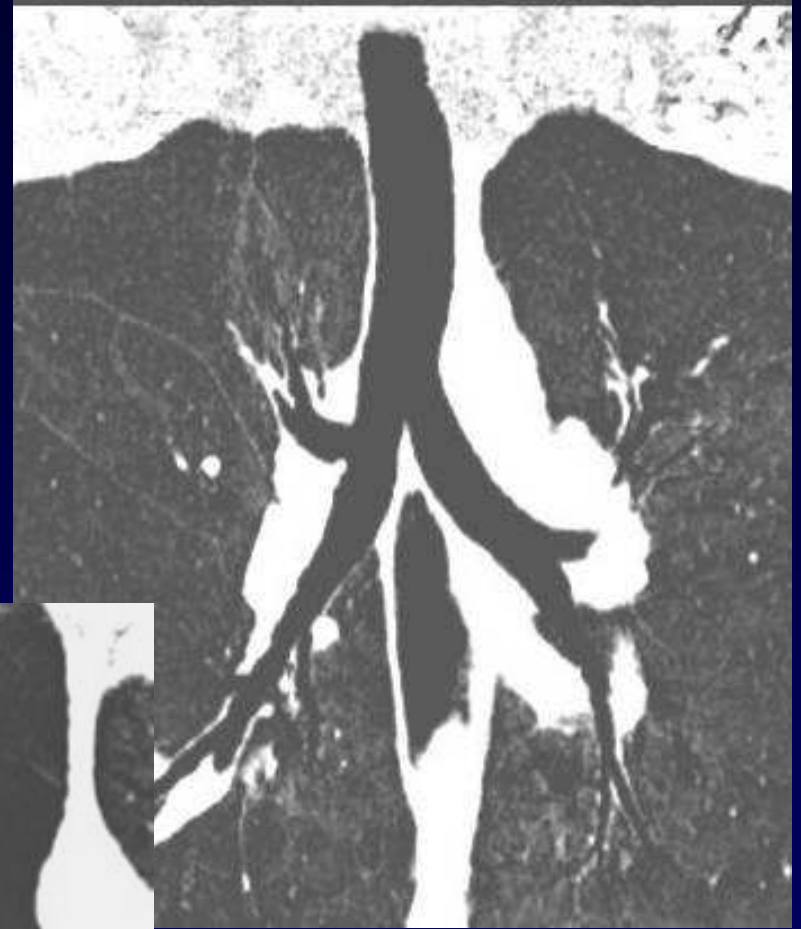
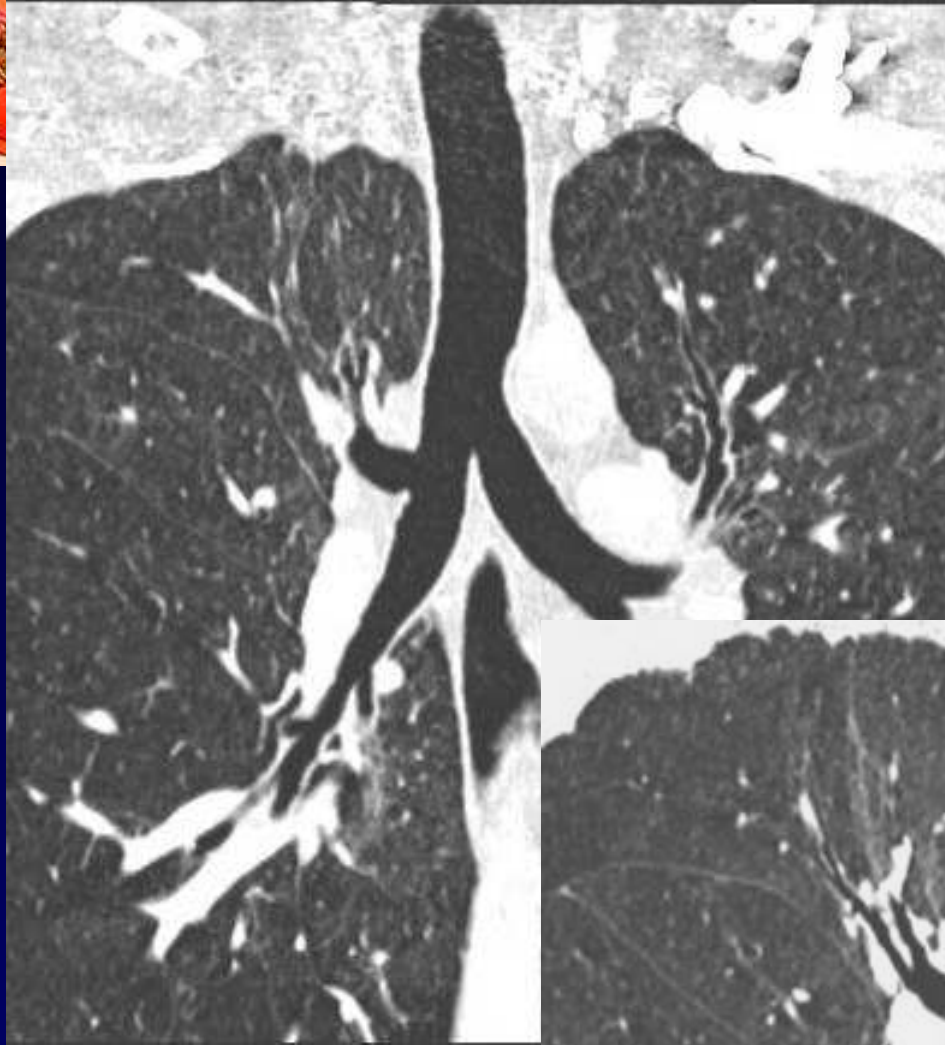


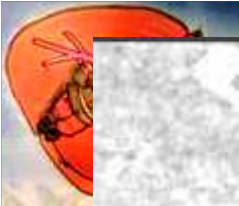Homme de 33 ans

- Cuisinier, Tabac ++ , asthme enfance
- Toux modérée, peu productive, dyspnée modérée.
- VEMS 78 %, DLCO normale
- Radio thorax jugée normale









Diagnostic ?



Diagnostic

Collapsus aéré du LSD avec
« glissement » de la BLSD

Codage : Poumon - Médiastin - Anatomie